



**PATIENT**

Dingo Warr

**PRESENTING CLINICAL SIGNS**

History: Pre-surgical. Arrhythmia on auscultation. No cardiac meds or history.

**SPECIES**

Canine

**ELECTROCARDIOGRAPHIC FINDINGS** \*Note: Single lead ECGs are evaluated as a rhythm strip. Morphology/MEA cannot be definitively commented on.

A single lead ECG is available; 25mm/s, 10mm/mV. The average heart rate is 150bpm with a largely regular rhythm. Low voltage complexes. P for every QRS complex and vice versa. The QRS morphologies is positive. Two isolated VPCs are identified in a 13 second tracing. The VPCs are monomorphic and singles. No supraventricular premature beats, pauses or other dysrhythmias observed. ECG diagnosis: Isolated VPCs.

**BREED**

Boxer

**SEX**

Female Spayed

**ECHOCARDIOGRAM FINDINGS**

2D, m-mode, color flow and doppler imaging is available. Normal mitral valve leaflets with no obvious prolapse into the left atrial lumen. No mitral or tricuspid regurgitation is identified. Borderline left atrial dimension. Normal LV diameter with normal myocardial function. The tricuspid valve appears subjectively normal, and there is no obvious tricuspid regurgitation. The right heart appears normal (subjective). No overt evidence of pulmonary arterial hypertension. The pulmonic and aortic valves are normal in morphology and mobility. No aortic abnormalities identified with a normal aortic outflow velocity, laminar flow. Normal pulmonic outflow velocities. No aortic or pulmonic insufficiency. No pericardial or pleural effusion noted. No cardiac tumors observed.

**AGE**

5 years

**WEIGHT**

78.3lbs

**CARDIAC CHART**

**INTERPRETED BY**

Maggie Machen Lamy,  
DVM, DACVIM  
(Cardiology)

CANINE CARDIAC PARAMETERS	MR VMAX (m/s)	TR VMAX (m/s)	LA/AO (Boon method)	LA/AO (Heart Base; Swe)	FS (%)	EF (%)	EPSS (cm)
NORMAL PARAMETER	4.5-5.5	<2.7	1.3	<1.6	28-40	40-100	<0.6
PATIENT	NA	NA	NM	1.2	34	70	NM
CANINE CARDIAC PARAMETERS	HR (BPM)	AV VMAX (m/s)	PV MAX (m/s)	BODY WEIGHT (kg)	LA 2D short axis Base view (cm)	LVIDd Avg; 2D and m-mode short axis (cm)	LVIDs Avg; 2D and m-mode short axis (cm)
NORMAL PARAMETER	50-100	0.7-1.7	0.7-1.6	BELOW	BELOW	BELOW	BELOW
PATIENT	NM	1.5	NM	35.5	2.4	4.1	2.7
*Normal chamber parameters expressed as a mean value (SD)				3	1.27 (5.3)	2.46 (2.46)	1.36 (5.5)
<b>BODY WEIGHT DEPENDENT PARAMETERS</b>				5	1.40 (4.5)	2.74 (5.2)	1.60 (4.7)
<i>*Note: All measurements based upon multi-modal images and methods. An average value is reported.</i>				10	1.50 (3.8)	3.27 (3.5)	2.06 (3.1)
				15	1.83 (2.0)	3.71 (2.4)	2.43 (2.1)
				20	2.02 (1.9)	4.14 (2.2)	2.80 (2.0)
				25	2.18 (2.4)	4.48 (2.9)	3.10 (2.5)
				30	2.33 (3.3)	4.83 (3.9)	3.39 (3.4)
				35	2.48 (4.3)	5.17 (5.0)	3.69 (4.5)
				40	2.62 (5.2)	5.48 (6.1)	3.96 (5.4)
				50	2.88 (7.1)	6.07 (8.3)	4.46 (7.4)

Adapted from June Boon, Veterinary Echocardiography, 1998  
Rishniw M and Hollis NE, J Vet Intern Med 2000; 14:429-435  
Hansson et al, Vet Rad and Ultrasound 2002  
Bonagura et al. Echocardiography: principles of interpretation, Vet Clin North Am 15:1177, 1995

**IMAGING PERFORMED BY**

Dana Alterman,  
RDCS, LVT

**HOSPITAL NAME**

Eubank Animal Clinic

**REFERRING VET**

Dr. Lloyd

**INVOICE**

21229

**DATE**

9/27/21



<b>PATIENT</b>	<b><u>INTERPRETATION OF THE FINDINGS &amp; FURTHER RECOMMENDATIONS</u></b>
Dingo Warr	Overtly normal cardiac structure and function with no abnormalities identified. The systolic function appears intact, and the right heart is subjectively normal.
<b>SPECIES</b>	Ventricular premature contractions (VPCs) were identified on the ECG. VPCs are generated from abnormal conductive or fibrotic tissue in the ventricles of the heart muscle, and even frequent single VPCs will often cause no clinical signs in dogs. When sustained however, ventricular tachycardia can lead to symptoms such as lethargy and collapse.
Canine	
<b>BREED</b>	VPCs are a very non-specific finding. They can be primary in origin (such as ARVC), be secondary to significant cardiac disease (not present in this study) or be extra-cardiac in origin, i.e., due to pain, stress, inflammation, cancer, GI disease, DIC/sepsis, etc. In this 5yo Boxer with RV origin VPCs, ARVC is suspected (most common age of onset is 6-8y). ARVC can occur with or without systolic dysfunction or structural issues, however this should be monitored going forward for any progressive changes. Recommend rule out other differentials for ectopy through AUS, tick titers, troponin, etc. Unfortunately, there is always an elevated risk for collapse and sudden death in any arrhythmic patient, and even on medications this risk unfortunately still persists. ARVC carries a HIGHLY variable prognosis, with some dogs able to remain asymptomatic for extended periods of time, and others developing exercise intolerance, syncopal episode, and refractory arrhythmias/sudden death imminently.
Boxer	
<b>SEX</b>	
Female Spayed	
<b>AGE</b>	
5 years	
<b>WEIGHT</b>	
78.3lbs	Based strictly upon the amount of arrhythmia present on the available ECG in this asymptomatic dog, anti-arrhythmic therapy is not clearly indicated. A holter monitor is highly recommended as the next step to allow monitoring of the rhythm throughout 24 hours of a normal day and help determine if treatment is indicated.
<b>INTERPRETED BY</b>	
Maggie Machen Lamy, DVM, DACVIM (Cardiology)	Fish oil supplementation is recommended for dogs with arrhythmias (1000mg of omega 3 and 6 once to twice daily). Mild activity/stress restriction is advised.
<b>IMAGING PERFORMED BY</b>	Monitor at home for collapse, exercise intolerance, and/or lethargy. If a holter monitor is elected, this will dictate whether therapy is needed and follow up protocol. I would not recommend anesthesia until the results are available if elected. If declined, an ECG should be monitored during general anesthesia and lidocaine administered in the event of sustained VT or malignant arrhythmias. Avoid stimulants such as atropine or glycopyrrolate unless indicated.
Dana Alterman, RDCS, LVT	
<b>HOSPITAL NAME</b>	No cardiac medications are indicated at this time. Monitor for any development of cough, labored breathing or exercise intolerance.
Eubank Animal Clinic	
<b>REFERRING VET</b>	<b><u>PLAN</u></b>
Dr. Lloyd	Holter monitor recommended. Consider systemic evaluation as discussed. If a holter is declined, recommend a recheck ECG is recommended in 2-3 months (sooner if any collapse episodes occur).
<b>INVOICE</b>	A recheck echocardiogram is recommended every 6-12 months to screen for development of dilation/dysfunction.
21229	
<b>DATE</b>	
9/27/21	



**PATIENT**

Dingo Warr

**SPECIES**

Canine

**BREED**

Boxer

**SEX**

Female Spayed

**AGE**

5 years

**WEIGHT**

78.3lbs

**INTERPRETED BY**

Maggie Machen Lamy,  
DVM, DACVIM  
(Cardiology)

**IMAGING  
PERFORMED BY**

Dana Alterman,  
RDCS, LVT

**HOSPITAL NAME**

Eubank Animal Clinic

**REFERRING VET**

Dr. Lloyd

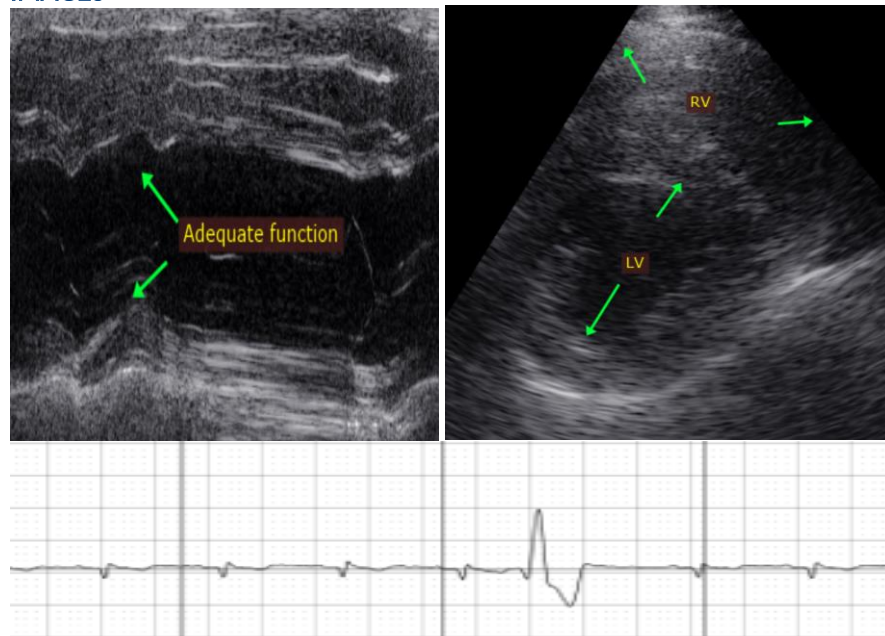
**INVOICE**

21229

**DATE**

9/27/21

**IMAGES**



The information and recommendations provided are based on the images presented by the referring veterinarian. No evaluation can be communicated regarding pathology that was not visible in the image/video clips provided.

Thank you for this referral. This report was generated using transcription software, and minor dictation errors may be present. If the clinical or image interpretation does not parallel your findings or if I can be of any further assistance, please contact me.

Maggie Machen Lamy, DVM  
Diplomate of the American College of Veterinary Internal Medicine (Cardiology)  
info@sonopath.com